

## **Chapter 13: Step-by-step guide: Subclavian CoreValve Evolut TAVR**

*Adam R Williams, MD and Jeffrey Gaca, MD*

Division of Cardiothoracic Surgery, Department of Surgery, Duke University

### **Essential or Key Steps**

- Size the valve using a high quality contrast enhanced computed tomography (CT)
- Assess the axillary/subclavian artery size using CT, it should be a minimum of 5mm to use the Evolut 14 Fr inline sheath
- Cut-down onto the left axillary artery and place vessel loops proximally and distally
- Obtain percutaneous femoral artery access for pigtail placement into non-coronary sinus and femoral venous access for the temporary pacer in RV
- Administer heparin 100 units/kg, goal act>250s
- Insert a 7-French sheath into left axillary artery
- Perform aortic root angiogram and obtain coplanar view
- Cross aortic valve
- If performing BAV, then exchange 7 Fr axillary sheath for 14 Fr Gore Dry Seal sheath and then perform BAV through this sheath
- Insert 14Fr Evolut Delivery System over stiff wire into left axillary artery
- Deploy valve
- Exchange Evolut R Delivery System over a stiff wire for 14 Fr Gore Dry Seal Sheath
- Assess valve by TEE and fluoroscopy
- Obtain post valve deployment hemodynamics
- Remove axillary artery sheath, repair artery and close wound
- Remove groin sheaths

### **Pearls and Pitfalls**

- The left subclavian artery is preferred over the right subclavian due to its natural curvature into the aortic arch
- Avoid using the subclavian artery if the patient has subclavian stenosis
- If there is a patent left internal mammary artery (LIMA) to a coronary artery graft, the minimum diameter of the subclavian artery should be at least 6mm when using the 14Fr inline sheath. However, we prefer to use another access site (such as the carotid artery) in the setting of a patent LIMA graft.
- There may be a prominent axillary fat pad overlying the vessels and removal of this with electrocautery facilitates exposure of the axillary artery.
- Identify the brachial plexus, which is superior to the axillary artery and avoid cauterizing near the nerve.
- Bilateral radial arterial lines are helpful as the arm with the sheath in place will have a dampened waveform.

- The axillary arteriotomy should be pinched with the thumb and index finger to limit bleeding during sheath exchanges
- When the dimensions fall on the upper limit and lower limit of 2 valve sizes, we usually select the larger valve size to minimize perivalvular leaks, except when there is significant annular or LVOT calcification we recommend using the smaller valve size.

## **Introduction**

Femoral artery access is the preferred route for transcatheter aortic valve replacement (TAVR). Occasionally severe atherosclerosis or limited size of the iliofemoral vessels may require alternative access vessels. The axillary artery, carotid artery, direct aortic, and left ventricular transapical are the most commonly used alternative access sites.<sup>1</sup> When the femoral arteries are not suitable, our second choice is to use the left axillary artery for vascular access and the CoreValve Evolut (Medtronic, Minn, MN) transcatheter delivery system. The CoreValve is a tri-leaflet porcine pericardial tissue valve mounted on a self-expanding nitinol frame. The leaflets of the valve are mounted in a supra-annular position to increase orifice area and the self-expanding nitinol frame conforms to the native annulus. The CoreValve Evolut is mounted on the tip of a steerable catheter delivery system with a built in 14-French inline sheath allowing the whole system to be directly inserted into the subclavian artery for valve deployment.

## **Patient selection and preoperative planning**

A multidisciplinary team of interventional cardiologists and cardiothoracic surgeons evaluates each patient with severe symptomatic aortic stenosis referred for TAVR. A preoperative gated high quality contrast enhanced computed tomography (CT) is obtained on all potential TAVR patients to assess vascular anatomy and to determine the size the valve to be implanted. We use TeraRecon (Foster City, CA) three-dimensional reconstruction software to assess the size, tortuosity, calcium distribution, and course of the vessels. If the iliofemoral vessels are not suitable due to severe atherosclerosis we then define the anatomy of the aortic arch and axillary artery. The axillary artery is the preferred alternative access because of its natural curvature into the ascending aorta gives the operator a better angle of valve deployment in the aortic annulus, but the right subclavian artery can also be used. Important considerations to assess are the origin of the subclavian artery from the aortic arch, presence of subclavian stenosis, and if there is a patent left internal mammary artery (LIMA) to a coronary artery graft. We recommend a minimum size of 5mm for the axillary artery when using the CoreValve 14-Fr inline sheath. A patent LIMA graft is not a contraindication to using the axillary approach, but the minimum diameter of the subclavian artery should be at least 6mm.<sup>1</sup> We prefer not use the left subclavian artery if there is a patent LIMA graft and use either the right axillary or trans-carotid approach to avoid potential myocardial ischemia and injury to the LIMA graft.

Measurements of the annulus, sinuses of valsalva, sinotubular junction, and coronary heights are determined using the 3-D reconstruction of the aortic root. The size of the valve to be implanted is determined based on these measurements and using the CoreValve Evolut R reference card. We use the average diameter of the annulus to size our valves, however, many use the annulus perimeter. When the dimensions fall on the upper limit and lower limit of 2 valve sizes, we usually select the larger valve size to minimize perivalvular leaks.

## Steps in axillary CoreValve Evolut TAVR

The patient is positioned supine on the hybrid OR table. The cardiac anesthesia team administers general endotracheal anesthesia and places a transesophageal echocardiography (TEE) probe. Bilateral radial arterial line placement is very helpful in this deployment scenario. The valve deployment sheath will dampen the ipsilateral radial arterial line and give an inaccurate blood pressure reading. The contralateral radial arterial line will display the appropriate blood pressure during valve deployment. Similarly, after repair of the axillary artery, the ipsilateral arterial line should display the appropriate pulsatile blood pressure. The patient is prepped and draped from chin to mid thighs. We always have cardiopulmonary bypass set-up in our hybrid OR with perfusion on stand-by in case emergency support is needed.

### Vascular access:

1. A 4-5cm transverse incision is made 1-2 finger breadths below the lateral 2/3rds of the left clavicle. (Figure 1)
2. Dissection is carried down to the pectoralis major fascia and divided with electrocautery. The deltopectoral groove is entered and clavipectoral fascia divided.
3. Pectoralis minor is divided with cautery.
4. The left axillary artery is identified. The brachial plexus is typically located superior and axillary vein located inferior to the artery. *Tip: There may be a prominent axillary fat pad overlying the vessels and removal of this with electrocautery facilitates exposure of the axillary artery.*
5. The artery is dissected free over a length of several centimeters and vessel loops placed proximally and distally. *Tip: Small branches from the axillary artery are ligated with 2-0 silk ties and occasionally the thoracoacromial branch may need to be ligated to ensure wide mobilization of the artery.*
6. A separate 1cm stab incision is made lateral to the transverse axillary incision. An access needle is inserted through the stab incision into the left axillary artery and a J-tipped wire inserted into the vessel. A 7-French sheath is inserted into the axillary artery over the wire. (Figure 2)
7. The left common femoral artery is accessed percutaneously using a micropuncture needle and catheter. The micropuncture catheter is exchanged for a 5-French sheath.
8. The right common femoral vein is accessed with a micropuncture needle and exchanged for a temporary transvenous pacemaker locking sheath. The temporary tranvenous pacer is then advanced into the right ventricle using fluoroscopy while the balloon tip is inflated. The pacer is then tested by pacing at a rate higher than the intrinsic rate.
9. The patient is then systemically anticoagulated with heparin (100 units per kg) to a goal activated clotting time (ACT) greater than 250 seconds. An ACT is checked every 15 minutes and heparin re-administered as needed to maintain an ACT greater than 250 seconds.

### Crossing the aortic valve:

10. A J-tipped wire is passed from the left artery femoral sheath into the aortic root. A pigtail catheter is exchanged over the wire and positioned into the non-coronary sinus.

11. The C-arm is positioned in the implant view obtained from the preoperative CT. Multiple aortic root angiograms are performed with necessary adjustments to the C-arm to obtain the optimal implant view with aortic cusps aligned and the annulus in a planar view.
12. A J-tipped wire is backloaded on a 6 French AL-1 catheter and advanced through the left axillary 7-French sheath into the ascending aorta. The J-tipped wire is then exchanged for a soft straight-tip wire.
13. The aortic valve is then crossed with the straight tip wire and the AL-1 advanced into the left ventricle (LV). *Tip: Identify the aortic jet on the aortic root angiogram and save the image to one of the screens for reference. The aortic jet can be located by slowly manipulating the wire tip in the aortic root and when the straight tip wire gets kicked out you will be in the jet. Usually the aortic jet is just to the screen left of the non-coronary sinus.*
14. Once across the aortic valve, the straight tip wire is exchanged for a J tipped wire and then a 6 French pigtail catheter is passed over this wire and positioned into the LV apex. *Tip: Take the time to position the pigtail along the septum into the apex without it getting caught in the papillary muscles.*
15. The LV and aortic hemodynamics are recorded and an aortic valve gradient obtained.

### **Valve Implantation:**

16. A deployment wire (either a Confida or a Safari S2 wire) is then inserted into the left subclavian pigtail and introduced into the LV apex. The pigtail and 7-French sheath are removed from the left axillary artery with the wire left in place. *Tip: The arteriotomy in the vessel is pinched with the thumb and index finger to limit bleeding as the sheath is removed.*
17. If pre-implantation balloon valvuloplasty is planned, then a 14-French Gore Dry Seal sheath is placed in the axillary artery and an appropriately sized balloon catheter is passed over the stiff wire across the aortic valve. Note: this 14-French sheath must be exchanged after balloon valvuloplasty for the 14-French in line Core Valve Evolut sheath for valve deployment. Alternatively, if the vessel diameter is large enough (>6.0 mm), the entire case can be performed using an 18-French Gore Dry Seal sheath. Whether using an 18-French sheath or the 14-French in line Core Valve deployment sheath, the sheath cannot be advanced to its full length inside the axillary artery such as is done with femoral deployment. The tip of each sheath should only be advanced to the origin of the left subclavian artery in the aortic arch and no further. If either sheath is advanced too far into the ascending aorta, the sheath will interfere with valve deployment as the top of the valve frame will remain inside the sheath. This will leave a considerable length outside of the artery and it is important to maintain control of this sheath at all times as it is easily ejected. Once, the preferred sheath is in the correct position, rapid ventricular pacing is done with a rate of 160-180 beats per minute while inflating the balloon. Typically, we utilize a 18mm True balloon for pre-dilation as a full balloon aortic valvuloplasty is not necessary for the Core Valve device. *Tip: We typically do not perform a pre-implant balloon valvuloplasty when implanting the Core Valve.*
18. The CoreValve Evolut R is then placed through the separate stab incision and into the axillary artery over the stiff wire and advanced under fluoroscopy across the aortic valve. (Figure 3)
19. The landing zone is identified based on the pigtail in the non-coronary sinus, calcification of the native valve, and repeated aortic root arteriograms. The ideal implant depth is 3-6mm below the nadir of the coronary sinuses. We attempt to deploy the valve as high in the annulus as possible to minimize the permanent pacemaker rate without increasing the rate of paravalvular leak.(Figure 4)

20. The valve is then slowly deployed to 2/3 of the full deployment, at which time the valve is fully functional (Figure 4C). We then assess with TEE and aortic root angiograms the depth of the valve. At 2/3 deployment the CoreValve Evolut R can be recaptured if it appears to be seated too deep or too high, repositioned and then deployed again. When appropriate depth is obtained, the valve is then fully deployed (Figure 4F).
21. Once the valve is deployed, TEE is done to ensure proper opening of the leaflets, assess depth of the valve, and identify any perivalvular leaks. We usually accept mild perivalvular leaks as this typically gets better as the frame warms up to body temperature, however, anything greater than mild should be addressed with balloon valvuloplasty. We typically size the post implant balloon to the minor axis of the aortic annulus. For balloon post-dilatation, we favor a softer, more conformable balloon such as the Z-Med II than the stiffer, less conformable True balloon.
22. The CoreValve Evolut R system is then removed over the stiff wire and a 14 French Gore Dry Seal Sheath (Newark, DE) is inserted into the left subclavian artery for hemostasis.
23. A 6-French pigtail is then inserted over the stiff wire into the LV apex and the wire removed.
24. Post implant hemodynamics are recorded in the LV and the ascending aorta. A valve gradient is calculated. *Tip: It is important to assess the diastolic separation between the aorta and LV when a significant perivalvular leak is present.*
25. The LV pigtail is then pulled back into the ascending aorta and an aortic root angiogram is performed to assess the valve and perivalvular leaks.
26. Both pigtails are removed from the body.

**Closure:**

27. Proximal and distal angled DeBakey clamps are placed on the left axillary artery as the 14-French Gore Dry Seal sheath is removed.
28. Multiple interrupted 5-0 Prolene (usually at least three) are used to repair the arteriotomy in the left axillary artery. The clamps are then removed and the distal axillary artery pulsation is assessed as well as hemostasis. At this point, a left radial arterial line is helpful to confirm the return to pulsatile flow to the left radial artery. *Tip: Additional 5-0 prolene sutures may need to be placed for hemostasis but we wait for reversal of heparin before fully assessing hemostasis and placing additional sutures.*
29. Protamine is then administered.
30. The axillary incision is then closed in layers using 0-Vicryl for the pectoralis fascia, 2-0 Vicryl for the subcutaneous tissue, and 3-0 monocryl subcuticular stitch for the skin. The stab incision is closed with just a 3-0 monocryl subcuticular stitch.
31. The left femoral sheath is removed and pressure held for 10-15 minutes or a Perclose ProGlide (Abbott, Santa Clara, CA) can be used for closure.
32. If the rhythm is stable and does not require pacing, the temporary pacer and sheath are removed and pressure is held. If pacing is required, we then place a temporary screw in lead via the internal jugular vein and then remove the femoral pacer.
33. The patient is extubated in the operating room and transferred to the cardiac intensive care unit. The patient is transferred to the cardiac step-down unit on postoperative day 1 and usually home on postoperative day 3.

## Potential Complications

Vessel injury is always a potential complication with any vascular access during TAVR. The subclavian and axillary artery is usually spared from severe atherosclerosis making it an excellent vessel for vascular access. We always do a cutdown on the axillary artery and directly repair the vessel after removing the sheaths, so we have not experienced any postoperative bleeding complications. Furthermore, we inspect the distal axillary artery pulse and ensure the arm is fully reperfused before closing the incision. Again, a left radial arterial line is helpful in this scenario. The chest wall has a robust blood supply and is typically a clean area, unlike the groins, making wound infection of the axillary incision uncommon. Other complications seen in TAVR such as annular rupture, significant perivalvular leak, and need for permanent pacemaker still occur.<sup>2</sup>

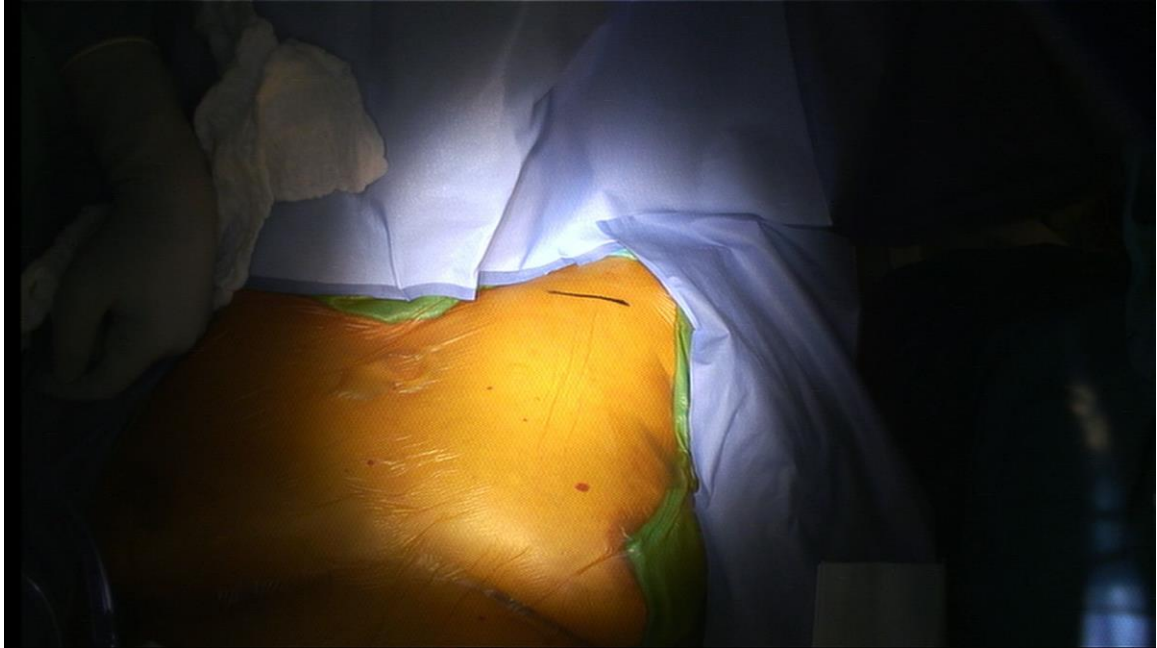
## Conclusion

The subclavian approach is an excellent option for patients that do not have adequate femoral access for TAVR. The natural curvature of the left subclavian artery into the ascending aorta and short distance to the aortic valve allows for easy crossing of the valve as well as fine adjustments to be made during valve deployment. Furthermore, the CoreValve's 14-French inline sheath allows the whole system to be directly inserted into the subclavian artery. The trans-subclavian approach has been shown to be a safe, easy, and reproducible alternative access for TAVR.<sup>2-3</sup>

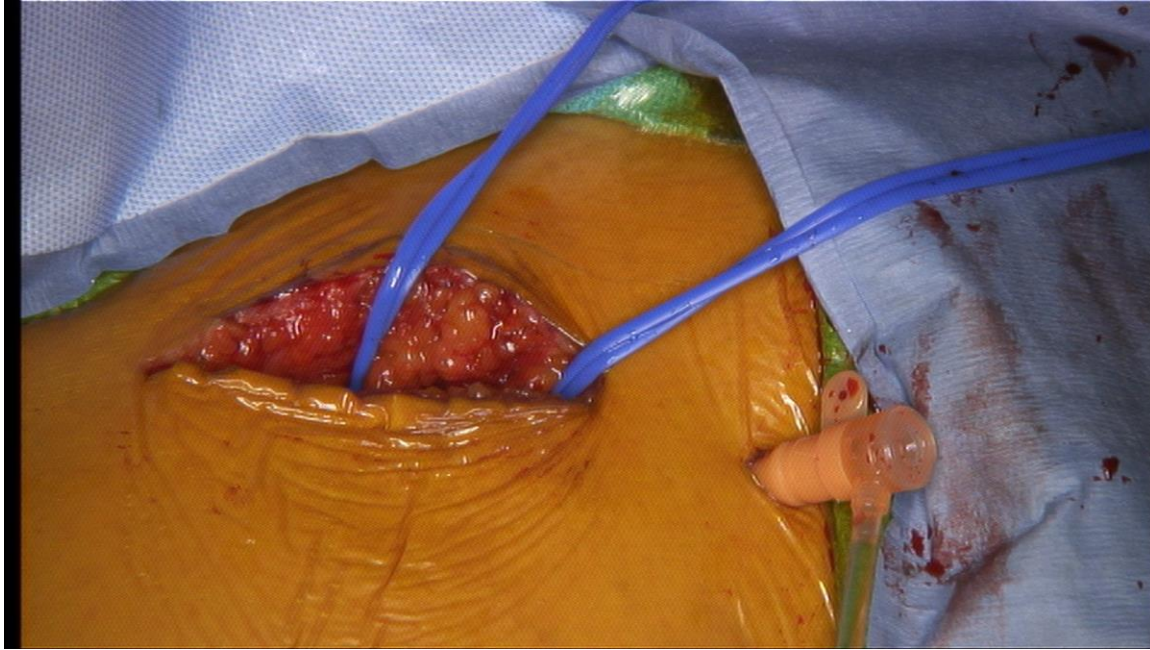## References:

1. Ramlawi B, Anaya-Ayala JE, Reardon MJ. Transcatheter aortic valve replacement (TAVR): Access planning and strategies. *Methodist DeBakey Cardiovasc J* 2012;8(2):22-25.
2. Fraccaro C, Napodano M, Tarantini G, Gasparetto V, Gerosa G, Bianco R, Bonato R, Pittarello D, Isabella G, Iliceto S, Ramondo A. Expanding the eligibility for transcatheter aortic valve implantation: The trans-subclavian retrograde approach using the III generation CoreValve Revalving system. *JACC: Cardiovasc Interv* 2009;2(9):828-33.
3. Petronio AS, De Carlo M, Bedogni F, Marzocchi A, Klugmann S, Maisano F, Ramondo A, Ussia GP, Etori F, Poli A, Brambilla N, Saia F, De Marco F, Colombo A. Safety and efficacy of the subclavian approach for transcatheter aortic valve implantation with the CoreValve revalving system. *Circ Cardiovasc Interv* 2010;3:359-366.

**Figure 1.** Left axillary incision site.

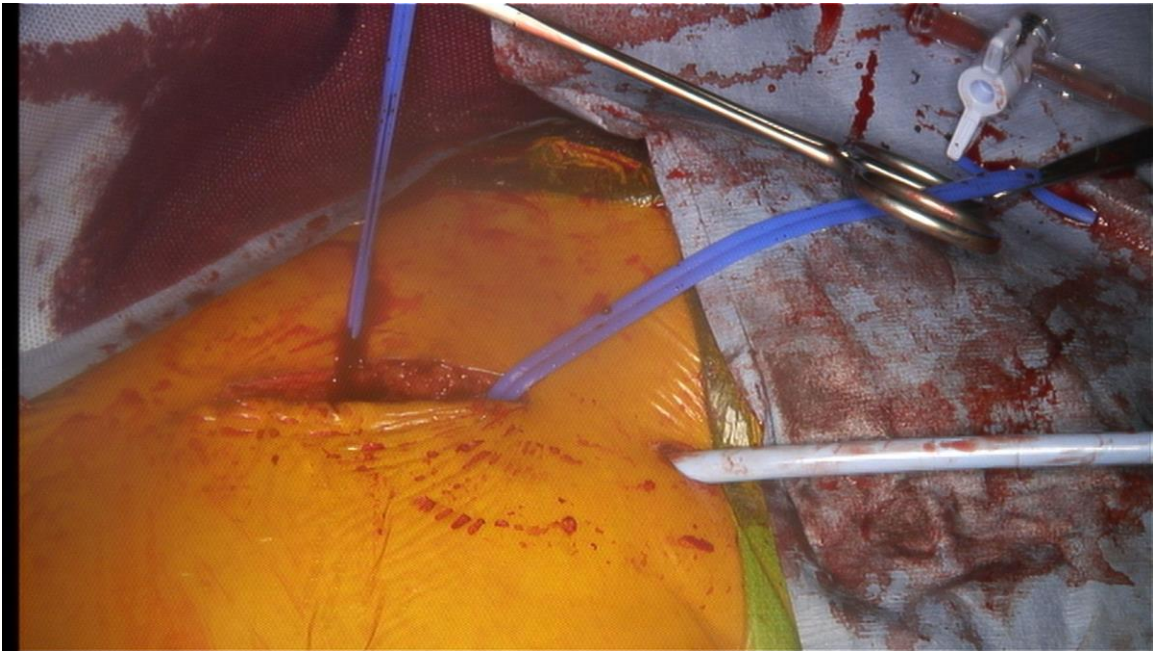


**Figure 2.** 7-French introducer inserted through separate stab incision into left axillary artery. Wire and catheter are passed through this introducer to cross valve.





**Figure 3.** CoreValve Evolut inserted through separate stab incision into axillary artery



**Figure 4.** Left axillary deployment of CoreValve Evolut. (A) Deployment starts with valve 6mm below the pigtail. (B) Valve is slowly deployed and the systemic pressure will fall during this stage. (C) Valve is fully functional at 2/3 deployment and can be recaptured and repositioned up to this point. (C-E) Completion of deployment.

